

## WHITE MATTER AT VARIOUS STAGES OF ALZHEIMER'S DISEASE

Vania Karami<sup>1\*</sup>, Giulio Nittari<sup>2</sup>, Francesco Amenta<sup>3</sup>

<sup>1</sup> Master of biomedical engineering, Ph.D. student of telemedicine and telepharmacy, School of Pharmaceutical Sciences and Health Products, University of Camerino, Camerino, Italy

<sup>2</sup> Master of chemical and pharmacy technology, Ph.D. student of telemedicine and telepharmacy, School of Pharmaceutical Sciences and Health Products, University of Camerino, Camerino, Italy

<sup>3</sup> MD neurology, professor of anatomy School of Pharmaceutical Sciences and Health Products, University of Camerino, Camerino, Italy

\*Corresponding Author:-

### Abstract:-

**Background:** To determine whether the brain's white matter (WM) volume condition provides an accurate insight into the early diagnosis of Alzheimer's disease (AD).

**Objective:** Using an automatic system to measure WM from MR images in order to check the potential of WM atrophy to affect the progression of the AD and whether it can be used as a good biomarker.

**Methods:** We used the Open Access Series of Imaging Studies (OASIS) database. The method consists of a series of morphological operations on the binary images to extract WM volume and calculation of volume and the statistical characteristic of segmented WM.

**Result:** There is a significant negative correlation between WM volume and CDR ( $r=-0.432$ ,  $p<0.05$ ). The correlation between WM volume and CDR indicates that the severity of the current state of disease is associated with the loss of WM volume. While the AD has mostly been considered as a GM disease, this study approved that AD is characterized by the relevant involvement of the WM, and WM is a cognitive change in the AD.

**Conclusion:** Our results confirmed that WM volume significantly contributes to the prediction of the AD. A robust and accurate segmentation of WM lesions from MR images can provide importantly information about the disease status and progression.

**Keywords:** - Alzheimer's disease, AD diagnosis, White Matter (WM), Clinical Dementia Rating (CDR), biomarker

## 1. INTRODUCTION

Alzheimer's disease (AD) is a progressive neurodegenerative disease which mainly develops in old people. Neurodegenerative disease such as AD is associated with changing the brain structure. The AD has been known as the Gray Matter (GM) disease. However, recent studies [1] in AD patients showed evidence of the involvement of both White Matter (WM) and GM abnormalities. Pathological evidence suggested that WM damage even might occur independently of GM atrophy [2]. One study comparing longitudinally WM and GM changes in the AD over a period of 16 months [3]. They concluded GM and WM changes over time were only partially correlated [3]. Reduced WM volume is an effect of the AD. WM Deterioration is a sign of neurodegeneration and increased dementia risk [4]. A pathological study [5] demonstrated WM damage as an intrinsic and early pathogenic event of the AD. Nowadays, the studies about brain structures divide into two main groups: neuropathological studies and neuroimaging studies. Neuroimaging beside neuropathological methods can help to better understanding of WM damage in the AD. The combination of neuroimaging of Magnetic Resonance Imaging (MRI) and neuropathological tests has allowed researchers to obtain more about the pathophysiological mechanisms and more importantly has improved outcome in the drug trial of the AD. MRI provides better insight into WM structure. It has been introduced to make a clinical diagnosis of the AD in vivo with high specificity and validity. A study [6] to evaluate and track WM damage in the AD using MRI data over an average period of 16 months, concluded that a multimodal imaging approach may provide additional markers to monitor disease progression.

Individual biomarkers related to the brain structure may cause specific interventions in order to cognitive health enhancement. Unfortunately, these kinds of biomarker are not well established [4]. WM damage is a frequent result of neuropathological investigations of AD type dementia, with a prevalence of more than 50% [7]. A research on the WM indicated that WM microstructural damage is not always secondary to neural loss but more than one mechanism might be involved [8]. A pathological assessment [9] of neurologically normal controls with AD pathological diagnosis showed that in these subjects, WM abnormalities were not related to vascular disease. They suggested WM damages as an essential and early pathologic event in AD [9]. Since early diagnosis of the AD is an important step of cure procedure, WM and its change during the follow-up should be considered as important criteria in the AD. The assessment of WM volume loss may lead to a valid biomarker of clinical progression in many neurological disorders [10]. Some studies evaluated the extent and severity of WM in relation to their therapeutic responses to rivastigmine in AD [11]. The atlas based approach has been widely used to study WM over different regions [12]. Previous researchers mainly focused on a global measure of WM hyperintensity that denotes localized WM damage [6].

Clinical Dementia Rating (CDR) [13] is a global screening instrument to assess the subject's basic cognitive ability. A research [14] highlights that atrophy of specific brain regions are related to performance on the MMSE test and provides new insights into the cognitive function probed by these tests. Until now, little importance has been given to ascertain the relationship between clinical parameters and the image features to improve the diagnostic relevance [15]. The purpose of this study was to examine quantitatively the change of WM as the AD biomarker. In order to this, we used measure using the changes of brain structure associated with WM using an automatic system based on MR images. This aim was realized using Pearson correlation coefficient method.

## 2. Materials and methods

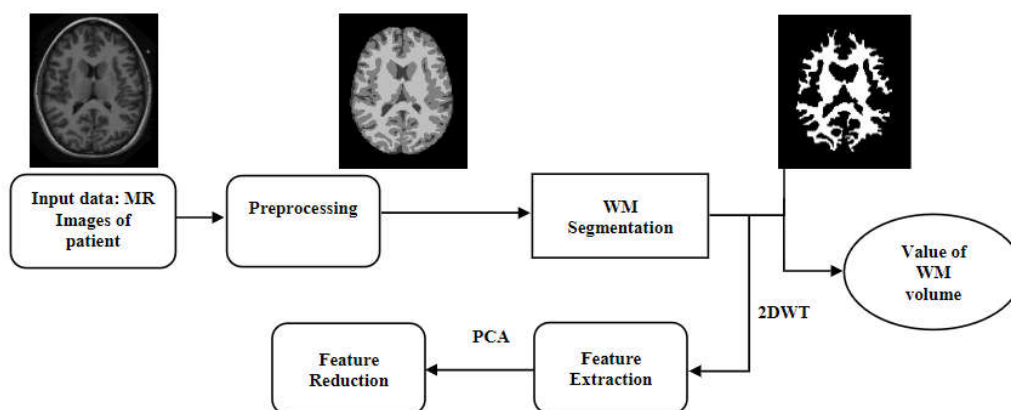
### 2.1. Subjects

The dataset in this study is the Open Access Series of Imaging Studies (OASIS) database [16]. This database consists of a cross-sectional collection of MR images of 416 subjects, both men, and women (mostly women), aged between 33 to 96 years old. The female subjects are more than the male because women live longer than men on average and older age is one of the most criteria for AD [17].

In this study, all subjects are 3D MRI scans in X-Y planes. Subjects are differentiated to three group based on a global Clinical Dementia Rating (CDR) scale [18] including normal with no dementia and CDR of 0, very mild AD (CDR=0.5) and mild AD (CDR=1).

### 2.2. Methods

Automatic extraction of WM: Computer method developments for early diagnosis of Alzheimer's disease (AD) can contribute significantly to undertake preventive/disease modifying measures. Computer Aided Diagnosis System (CAD) based on Magnetic Resonance (MR) image processing can improve medical analysis and interpretation. In this study, CAD consists of four main parts. Each part has its unique method but they have interrelation i.e. the output of one step is the input of the next step. CAD's procedure of this study is shown in figure 1. The first input of CAD is brain MR images of AD patients and the final outputs are the image of extracted WM, value of WM and some statistical features of WM.



**Figure 1. Block diagram of WM extraction by CADs.**

Preprocessing step adjusts voxel intensities and spatial normalization. All analyzed preprocessing was done by FreeSurfer software [19].

The method for WM extraction consists of a series of morphological operations on the binary images to achieve WM volume. The results of this step are WM region of the brain and the value of this volume.

Feature extraction and feature reduction from images were done using Single-level discrete 2D wavelet transform (2DWT) and Principle Component Analysis (PCA) [20], respectively. We chose DWT because it provides an efficient multi-resolution decomposition of images. Statistical features are defined in the distribution of the WM in the pixels of an image. There are different first order statistical features like Contrast, Energy, Entropy, Mean, Root Mean Square (RMS), Standard Deviation, Skewness, Kurtosis, Variance, and Homogeneity. It may be helpful to see the trend in the different severity of AD. The extracted features are used to identify the characteristic of segmented WM.

## 2.2. Statistical analysis

The trend of WM volume was compared between patients and controls. Data comparisons were adjusted for CDR, based on it, subjects are divided into three different classes. The change of WM in all groups was assessed. Significant results were considered at  $p < 0.05$ . We used the Pearson correlation coefficient test to association assessment between clinical and volumetric variables. All postprocessing of the MR images, as well as statistical analysis, are performed using MATLAB R2017a.

## 3. Results

### 3.1. WM extraction

Table 1 displays the results of the system for automatic WM extraction. This system is able to detect WM volume with accurately 98%.

Since the extracted WM is done perfectly, it is helpful to have the volume and other statistical features of WM as an important information in order to valid dementia diagnosis. Therefore, the ability of automatic calculation of this information is added to the system. These features can be used for post-processing analysis for other purposes. Table 2. Summarizes the extracted statistical features of the dataset.

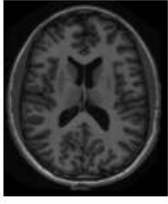
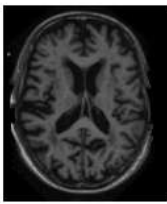
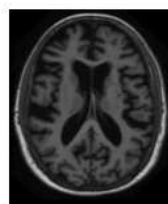
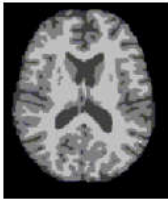
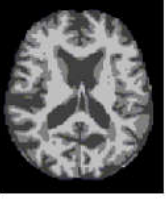
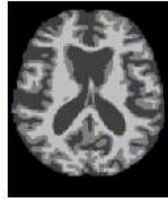



stages	Stage 1: Normal images	Stage 2: Very Mild AD	Stage 3: Mild AD
X-Y plane			
PREPROCESSED images			
EXTRACTED WM			
CDR	0	0.5	1

Table 1: The X-Y plane of the three images in the three stages.

Table 2. The extracted statistical features of the dataset.

CDR	CDR 0		CDR 0.5		CDR 1	
Mean, SD	Mean	SD	Mean	SD	Mean	SD
Contrast	0,28557	0,021301	0,28151	0,012408	0,28619	0,015661
Energy	0,77079	0,006166	0,77457	0,008604	0,76927	0,007893
Homogeneity	0,93524	0,001524	0,93644	0,002249	0,9348	0,002266
Mean	0,00383	0,001102	0,00346	0,000686	0,00397	0,000587
SD	0,08973	6,75E-05	0,08972	4,83E-05	0,08973	4,22E-05
Entropy	2,80456	0,063483	2,78092	0,034237	2,78764	0,038769
RMS	0,0898	0	0,17062	0	0,0898	0,255575
Variance	0,00809	4,22E-05	0,00809	3,16E-05	0,00808	3,16E-05
Kurtosis	12,49786	1,163231	12,78919	1,938669	12,93199	1,558777
Skewness	1,08466	0,16185	1,1595	0,142252	1,10997	0,214674

CDR: Clinical Dementia Rating, SD: Standard Deviation, RMS: Root Mean Square.

Volume calculation of WM for all patients of the dataset had significant results to see the main role of WM in the diagnosis of the AD. Figure 2 shows the value of WM volume versus CDR.

The correlation between WM volume and CDR is  $-0.432$ ,  $p < 0.05$ .

Figure 2. The changes of WM ( $\text{mm}^3$ ) on different stages of AD severity based on CDR.

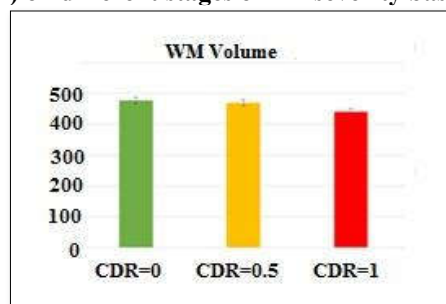
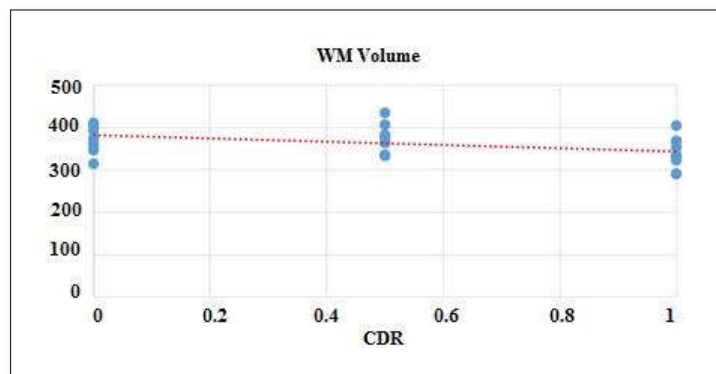


Figure 3. Correlation of CDR and WM volume ( $\text{mm}^3$ ) in different steps of the AD.



#### 4. Conclusion

In general, clinical diagnosis of the AD by specialists is still requiring a complete assessment that considers all possible causes through a series of clinical, psychometric, and brain scanning tests. Early diagnosis of the AD has received more attention due to the increasing number of AD patients in the world. Growing interests in the early diagnosis of AD leads to providing a valid quantification of dementia severity, which permits dementia progression determination, assessment of antidementia medications, and comparison. Since volumetric changes are approved in the AD, Volume estimation of different matters of the brain is important for many neurological applications [21].

Any noninvasive method such as a computerized system can assist the neurologist and will become increasingly important in clinical practice. Nowadays, CADs has become one of the major research subjects in medical imaging and diagnostic radiology to simplify the daily work of clinicians. It provides objective and quantitative volume data for prospective and retrospective analyses. This study has developed a new CADs to extract and analysis WM in order to assess the effect of the AD on WM. This system can automatically segment the WM from the brain, calculate its volume, and extract some statistical features of it. This presented computer method has been applied to our database. We chose CDR as an appropriate and global rating scale to determine the severity of disease in patients. Based on CDR, our dataset is divided into three different groups including controls, very mild AD and mild AD.

The AD has been mostly considered as a GM disease. However, recent in vivo neuroimaging studies approved WM abnormalities in this disease [8]; therefore, this study provides a concise insight into AD pathophysiology using the WM damage underlying noninvasive MR images. MRI is a method currently used to explore brain morphology. Our findings of decreased WM volume in AD patients is consistent with previous reports [22] and supports one of our first hypothesis of reduced WM volume in the AD. The change of WM volume with increasing the severity based on CDR is assessed. There is a significant correlation between WM volume and CDR ( $r=-0.432$ ,  $p<0.05$ ). We found a negative correlation between WM volume and CDR (figure 3), indicating that severity of the current state of disease is also associated with loss of WM volume. This suggests that WM is a cognitive change in the AD despite this belief that AD has been considered as a GM disease. This study approved that AD is characterized by the relevant involvement of the WM, while the mechanism of WM affection in AD remain largely unknown [23].

WM plays an important role in the characterization of the AD. Its relevant involvement approves what other postmortem and in vivo evidence showed [24]. WM volume, therefore, can be a quantitative biomarker and may be helpful for follow up on the AD during cure procedure. It may allow accurate individual follow-up and quantitative analogous to references. In this study, the automatic system of WM's volume calculation using MRI dataset provides WM changes in both early stage and typical AD. It can be concluded that this system has the ability to detect the WM changes before symptoms become clinically manifest. It also should be mentioned that microstructural damages of WM might be a useful tool for monitoring AD progression. Our novel method has the average linear accuracy of 95%. Since studies about WM damage in the AD have started recently, this valid function of the system may offer new possible targets for future therapies in the AD from a different point of view.

This system provides a new insight into the pathological mechanism of the AD using WM for physicians. In addition, they can use this system to improve the outcome of drug trials for AD patients.

This system has the ability to use a classifier in order to the diagnosis of AD types as the future work. Future work should assess and classify the extracted features of the PCA step to distinguish automatically different types of AD.

#### Acknowledge

The WM extraction procedure of this study wined the best poster presentation at the 11<sup>th</sup> international conference on AD and dementia, Vienna; Austria.

Data were provided by OASIS (Cross-Sectional: Principal Investigators: D. Marcus, R. Buckner, J. Csernansky J. Morris; P50 AG05681, P01 AG03991, P01 AG026276, R01 AG021910, P20 MH071616, U24 RR021382).

## References

- [1].Coleman M, Axon degeneration mechanisms: commonality amid diversity, (2005). Nature reviews neuroscience 6, 889-898, doi: 10.1038/nrn1788.
- [2].Brun A, Englund E: A white matter disorder in dementia of the Alzheimer type: a pathoanatomical study. (1986). Ann Neurol; 19:253–262.
- [3].Weiler M, Agosta F, Canu E, et al: Following the spreading of brain structural changes in Alzheimer’s disease: a longitudinal, multimodal MRI study. (2015). J Alzheimers Dis; 47:995– 1007.
- [4].Silbert LC, Lahna D, Promjunyakul NO, ET. Al, (2018). Risk Factors Associated with Cortical Thickness and White Matter Hyperintensities in Dementia Free Okinawan Elderly. J Alzheimers Dis. doi: 10.3233/JAD-171153.
- [5].De la Monte SM: Quantitation of cerebral atrophy in preclinical and end-stage Alzheimer’s disease. Ann Neurol 1989; 25:450–459, DOI:10.1002/ana.410250506.
- [6].Birdsill A, L. Kosciak R, M. Jonaitis E, ET. All, Regional white matter hyperintensities: aging, Alzheimer's disease risk, and cognitive function, (2014). Neurobiology of Aging, Volume 35, Issue 4, Pages 769-776.
- [7].Sjobeck M, Haglund M, Englund E: White matter mapping in Alzheimer’s disease: a neuropathological study (2006). Neurobiol Aging; 27:673–680.
- [8].Caso F., Agosta F., Filippi M., Insights into White Matter Damage in Alzheimer's disease: From Postmortem to in vivo Diffusion Tensor MRI Studies, (2016). Neurodegener Dis. ; 16(12):26-33. doi: 10.1159/000441422. Epub 2015 Dec 1.
- [9].De la Monte SM: Quantitation of cerebral atrophy in preclinical and end-stage Alzheimer’s disease, (1989). Ann Neurol; 25:450–459.
- [10].Pini L, Pievani M, Bocchetta M, Altomare D, Bosco P, Cavado E, Galluzzi S, Marizzoni M, Frisoni GB (2016): Brain atrophy in Alzheimer’s disease and aging. Ageing Res Rev 30:25–48.
- [11].Bo-Lin Ho, Yi-Hui Kao, Mei-Chuan Chou, Yuan-Han Yang, Cerebral White Matter Changes on Therapeutic Response to Rivastigmine in Alzheimer’s Disease, (2016). Journal of Alzheimer’s disease 54,351–357, DOI: 10.3233/JAD-160364, IOS Press.
- [12].Oishi, K., Faria, and A.: Atlas-based whole brain white matter analysis using large deformation diffeomorphic metric mapping: Application to normal elderly and Alzheimer’s disease participants. Neuroimage 46(2), 486–499 (2009).
- [13].Folstein, M.F., Folstein, S.E., McHugh, and P.R.: Mini-mental state A practical method for grading the cognitive state of patients for the clinician. J. Psychiatr. Res. 189–198 (1975)
- [14].Dinomais M, Celle S, Duval GT, Roche F, Henni S, Bartha R, Beauchet O, Annweiler C, Anatomic Correlation of the Mini-Mental State Examination: A Voxel-Based Morphometric Study in Older Adults, (2016).PLoS One. 14; 11(10):e0162889. doi: 10.1371/journal.pone.0162889. eCollection 2016.
- [15].Patil R.B., Ramakrishnan S. (2014) Correlation of Diffusion Tensor Imaging Indices with MMSE Score in Alzheimer Patients: A Sub-anatomic Region Based Study on ADNI Database. In: Pham T.D., Ichikawa K., Oyama-Higa M., Coomans D., Jiang X. (eds) Biomedical Informatics and Technology. Communications in Computer and Information Science, vol 404. Springer, Berlin, Heidelberg
- [16].<http://www.oasis-brains.org/>
- [17].Barnes J, Dickerson BC, Frost C, Jiskoot LC, Wolk D, van der Flier WM, (2015). Alzheimer's disease first symptoms are age dependent: Evidence from the NACC dataset. Alzheimers Dement;11(11):1349-57. doi: 10.1016/j.jalz.2014.12.007.
- [18].<https://surfer.nmr.mgh.harvard.edu/fswiki/DownloadAndInstall#Download>.
- [19].Lozano F, Ortiz A, Munilla J, Peinado A (2017) Automatic computation of regions of interest by robust principal component analysis.Application to automatic dementia diagnosis, *Knowledge-based systems*, vol. 13, no. C, pp. 229-237.
- [20].West J, Warntjes J. B. M, Lundberg P, Novel whole brain segmentation and volume estimation using quantitative MRI, (2012). Eur Radiol, 22:998–1007, DOI 10.1007/s00330011-2336-7.
- [21].Remika Mito R, Raffelt D., Dhollander T., N. Vaughan D., Tournier J.-D, Salvado O, Brodtmann A, C. Rowe C, Villemagne V L., and Connelly A, Fibre-specific white matter reductions in Alzheimer’s disease and mild cognitive impairment, (2018). Brain. 2018 Jan 4. doi: 10.1093/brain/awx355.
- [22].Amlin K, Fjell A. M, DIFFUSION TENSOR IMAGING OF WHITE MATTER DEGENERATION IN ALZHEIMER’S DISEASE AND MILD COGNITIVE IMPAIRMENT (2014).Neuroscience, Volume 276, Pages 206-215, <https://doi.org/10.1016/j.neuroscience.2014.02.017>.
- [23].Agosta F, Pievani M, Sala S, Geroldi C, Galluzzi S, Frisoni GB, Filippi M (2011) White matter damage in Alzheimer disease and its relationship to gray matter atrophy. Radiology 258:853–863. Alves GS, O’Dwyer L, Jurcoane A, Oertel-Kno“chel V, Kno“chel.